

Case Report

Extranasopharyngeal Angiofibroma from Hypopharynx: a Rare Case Report

Angiofibroma Ekstranasofaring dari Hipofaring: Laporan Kasus yang Langka

Ratna Windyaningrum*, Agung D Permana, Ongka M Saifuddin

Department of Otorhinolaryngology, Head, and Neck Surgery, Faculty of Medicine Universitas Padjadjaran / Hasan Sadikin General Hospital, Bandung, Indonesia.

Jl. Pasteur No. 38 Bandung, Jawa Barat 40161

*Corresponding author

Email: ratnawindyaningrum0708@gmail.com

Received: January 13, 2021

Accepted: January 21, 2022

Abstract

Angiofibroma is a histologically benign mesenchymal tumor though it is a potentially locally destructive fibrovascular tumor. Angiofibroma located in the head and neck comprises nasopharyngeal and extra-nasopharyngeal angiofibroma. The extra-nasopharyngeal angiofibroma itself is extremely rare. There was only two hypopharynx angiofibroma case in the recent literature. The aim of this report is to find out recurrence rate after mass extirpation surgery approach transcervical in this patient. A case of extra-nasopharyngeal angiofibroma from hypopharynx that arising from the left posterior pharyngeal wall was described in this report. A 32 years old man was admitted with 8 years history of lump located around the mouth and left side of the throat. There were no other significant complaints other than the lump itself. Histopathologic microscopic examination showed an angiofibroma. Angiofibroma is a benign and slow-growing mass. The conclusion is management of this case is the same as angiofibroma in general, by surgery approach. The mass was successfully removed surgically and thus far no recurrence or post-surgical complications were found one year after excision.

Keywords: angiofibroma; extra-nasopharyngeal; hypopharynx; pharyngeal mass

Abstrak

Angiofibroma merupakan tumor mesenkimal yang secara histologi jinak, meskipun tumor fibrovaskular ini dapat bersifat destruktif secara lokal. Angiofibroma yang terletak di kepala dan leher meliputi angiofibroma nasofaring dan ekstranasofaring. Angiofibroma nasofaring sendiri merupakan jenis yang sangat jarang. Hanya terdapat dua kasus angiofibroma hipofaring dalam literatur. Tujuan laporan kasus ini untuk mengetahui tingkat rekurensi setelah tindakan operatif ekstirpasi massa dengan pendekatan transervikal pada pasien ini. Sebuah kasus ekstranasofaring angiofibroma yang berasal dari hipofaring yang tumbuh pada dinding faring posterior dipaparkan pada kasus ini. Seorang pasien laki-laki berusia 32 tahun dengan riwayat memiliki benjolan di sekitar mulut dan sisi kiri tenggorokan selama 8 tahun. Tidak terdapat keluhan signifikan lain selain benjolan tersebut. Pemeriksaan mikroskopik histopatologi menunjukkan sebuah angiofibroma. Angiofibroma merupakan massa jinak yang tumbuh lambat. Kesimpulannya adalah penatalaksanaan pada kasus ini sama dengan angiofibroma pada umumnya, yaitu dengan pembedahan. Tumor tersebut berhasil diangkat secara pembedahan dan tidak terdapat rekurensi atau komplikasi pasca pembedahan satu tahun setelah eksisi.

Kata kunci: angiofibroma; ekstranasofaring; hipofaring; massa faring

Case Report

Introduction

Angiofibroma is commonly found in the nasopharynx.^{1,2,3} It is relatively rare and represents only 0.05% of all head and neck masses.^{4,5,6} Generally, angiofibromas present as an asymptomatic mass and slowly enlarges.¹ It appears to behave in a benign fashion. Diagnosis of angiofibroma is challenging if it is based on clinical symptoms and findings alone, the exact diagnosis requires histopathological and immunohistochemical staining microscopic examination results.⁷ There have been several studies describing nasopharyngeal angiofibromas however there have only been a few which report extra-nasopharyngeal angiofibromas, specifically in the region of hypopharynx.^{1,2} In this report, a case of hypopharynx angiofibroma arising from the left posterior pharyngeal wall in a young male was described, including the macroscopic characteristics, imaging, and histological findings. The aim of this report is to find out recurrence rate after surgery in this patient.

Case Illustration

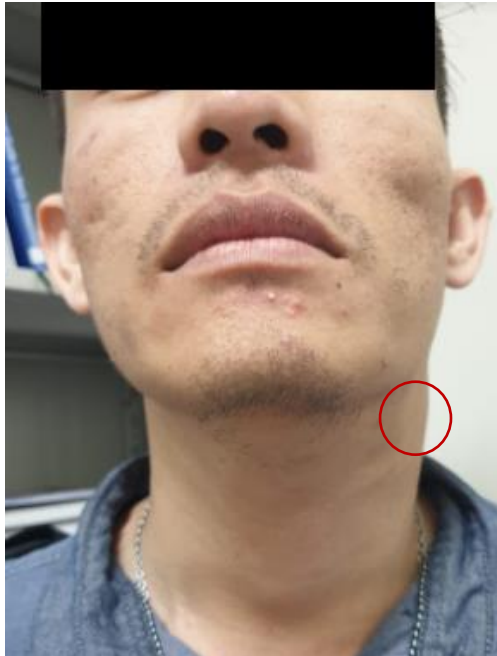The patient in this report provided written informed consent for the case publication. This study was approved by the patient himself and his family. A 32 years old man was admitted with 8 years history of a lump located around the mouth and left side of the throat. The patient complained of feeling something odd at the mentioned location since 2012 and has been increasing in size since 2014. He didn't complain of any difficulty during eating or drinking. History of dyspnea, hoarseness, double vision, hearing loss, and epistaxis was denied. He was an active smoker 10 years ago with 5 cigarettes per day. There was no history of salted fish consumption nor hypertension.

Physical examination revealed the patient was fully alert and looked moderately sick. Vital signs were all within normal limits. Local examination findings were mass at left hypopharynx region covering one-fourth of the posterior oral cavity, palpable at IIa-IIb level of left neck region with 7 x 6 x 3 cm in size, hard consistency, fixated, no tenderness, and no hyperemia (Figure 1).

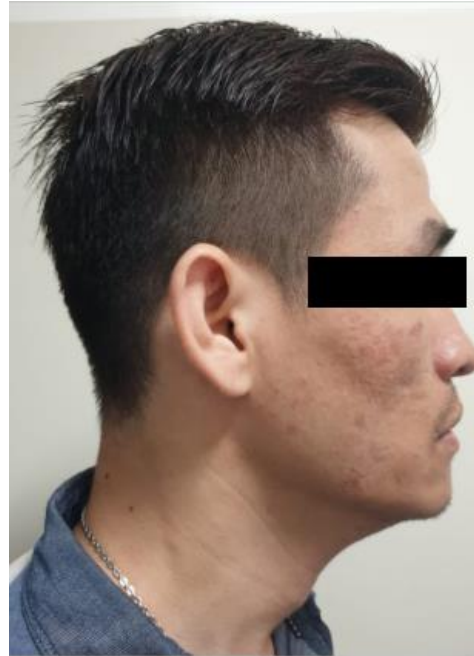A computed tomography (CT) scan revealed an inhomogeneous semisolid mass (hypodense lesion), well-circumscribed with irregular border accompanied with calcification and hemorrhage (hyperdense lesion). The size of the mass was 5.5 x 6.0 x 7.5 cm at posterior oropharyngeal wall obliterating bilateral palatine tonsils, long of head and neck bilateral muscles, left posterior digastric muscle, superior constrictor pharyngeal muscle, parapharyngeal space, and surrounding vascular attached to the left parotid gland. Right nasal

Case Report

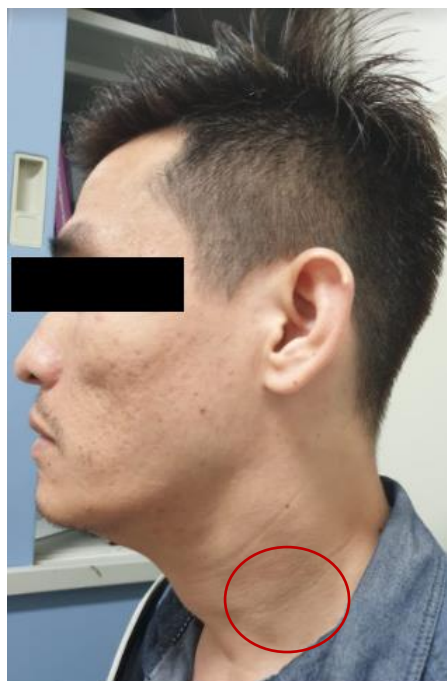conchae hypertrophy was also found (Figure 2).



A. Anterior View



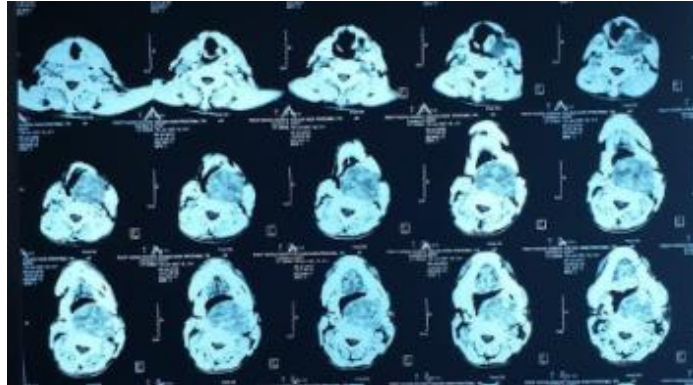
B. Right Lateral View



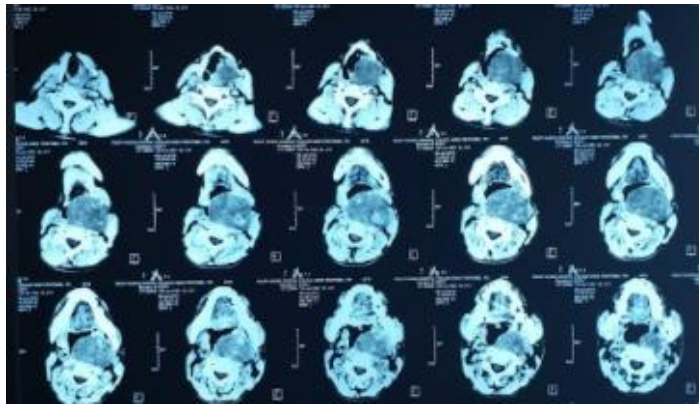
C. Left Lateral View

Figure 1 Pre-operative Lump Examination

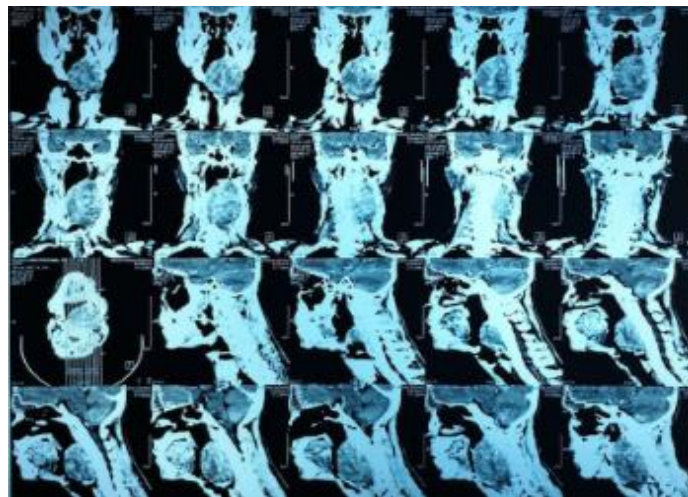
Case Report



A. Axial CT



B. Axial CT



C. Coronal CT

Figure 2 CT Scan Reveals an Inhomogeneous Semisolid Mass (Hypodense Lesion), Well Circumscribed with Irregular Border Accompanied with Calcification and Hemorrhage (Hyperdense Lesion)

A, B. Axial CT scan described the mass obliterating the palatine tonsils bilateral, long head and neck muscles bilateral, and left posterior digastric muscle. C. Coronal CT described the mass obliterating parapharyngeal space and vascular structure around that attached to left parotid gland.

Case Report

Fine Needle Aspiration Biopsy (FNAB) was done with no sample successfully obtained. The patient was suspected of having a hypopharynx mass. A preoperative tracheostomy and mass biopsy by micro laryngoscope approach was done. The macroscopic finding was a rubbery solid white brownish tissue with 8 x 6.5 x 3.5 cm in size. Then the mass was removed surgically approach transcervical incision. The mass attached to the left posterior digastric muscle and vascular structure around. (Figure 3).

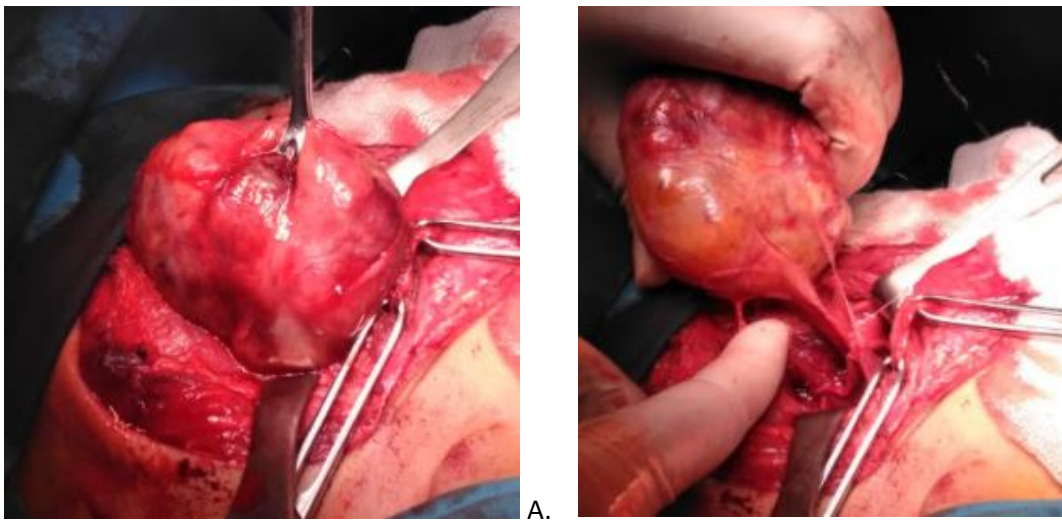


Figure 3 Intra-operative Mass Excision.

A. A rubbery solid white brownish tissue with 8 x 6.5 x 3.5 cm in size. B. The mass attached to left posterior digastric muscle and vascular structured around.

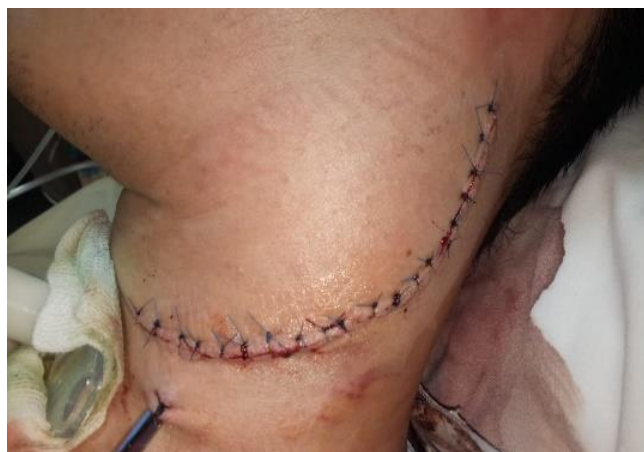

Figure 4 Post Operative Excision

Histopathologic microscopic examination showed an angiofibroma at the left hypopharynx region and no sign of malignancy. (Figure 5). Immunohistochemical examination revealed negative S100, positive CD34, vimentin, and Ki67. (Figure 6).

Case Report

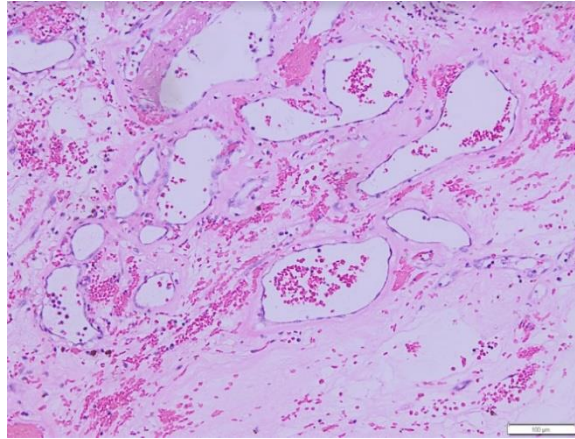
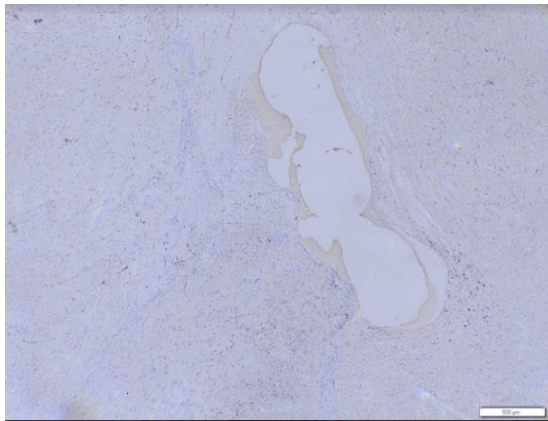
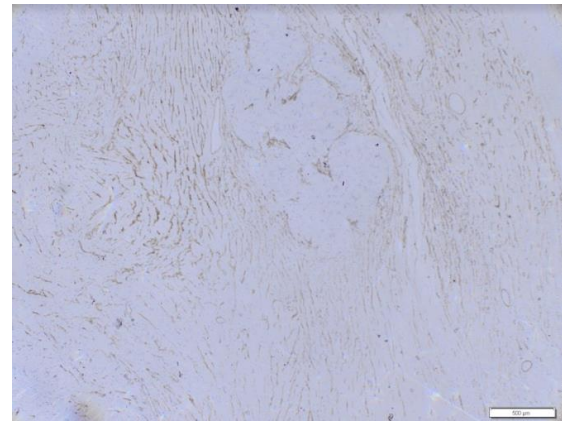


Figure 5 Histopathologic Microscopic Examination (Magnification 100x)

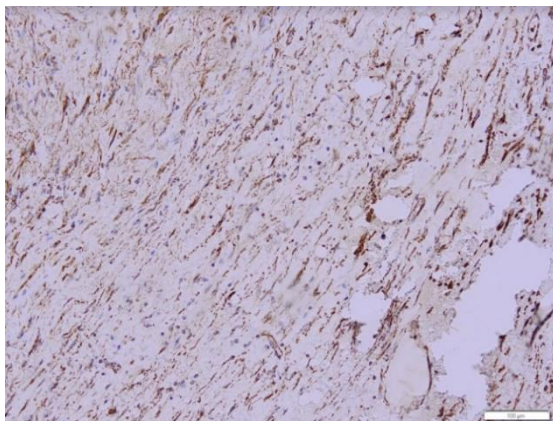
Figure shows a benign mass consists of fibro-collagenous stroma connective tissue with partly hyaline degenerated, with proliferating fibrocytes, mild amount of lymphocytes, endothel proliferation forming small vascular with nucleus within normal limit, necrotic area and extensive hemorrhage, and no sign of malignancy.



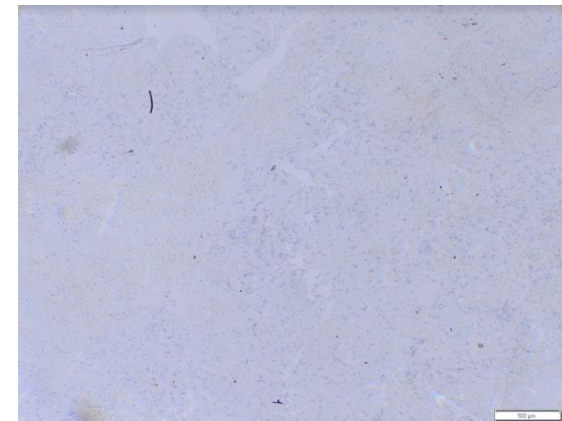
A. S100 (Magnification 100x).
Shows IHC Negative



B. CD34. (Magnification 20x).
Shows IHC Positive



C. Vimentin (Magnification 100x)
Shows IHC Positive



D. KI67 (Magnification 20x)
Shows IHC Positive

Figure 6 Immunohistochemical Examination

Case Report

Discussion

Angiofibroma is a histologically benign mesenchymal tumor though it is a potentially locally destructive fibrovascular tumor. It is commonly found in the nasopharynx.^{1,2,3} It is relatively rare and represents only 0.05% of all head and neck masses. It is usually found in young adolescent males.^{4,8} One study suggested that significant downregulation of miRNA 125a-5p is believed to stimulate miRNA tumor growth by the loss of this tumor suppressor.^{9,10,11}

Angiofibroma located in the head and neck comprises nasopharyngeal and extra-nasopharyngeal angiofibroma.^{3,12} There are a variety of sites of extra-nasopharyngeal angiofibromas which can include the nasal septum, the tonsils, the ears, the trachea, the larynx, and the ethmoid and sphenoid sinus.^{3,13,14,15} The extra-nasopharyngeal angiofibroma itself is extremely rare. There was only two hypopharynx angiofibroma in the recent literature.¹ Both of the studies reported smooth, firm, rubbery mass arising from the pharyngeal wall of the hypopharynx. They showed scatter fibrovascular tissue or fibro-myxomatous stroma harboring numerous blood vessels of various sizes and shapes.^{1,4} These findings are similar to the findings in this case report. However, only one of it conducted an immunohistochemical staining examination which revealed strong positivity for CD34 and negative staining for S100 protein as it is also the same in this report. Other than that, we found positive vimentin and Ki67. The presence of Ki67 is a cellular marker for proliferation and is strictly associated with cell proliferation.^{16,17}

In this case report, there was no significant disturbing complaint from the patient other than the lump itself. This finding is similar to the one which reported that the patient only had abnormal throat sensation and denied any history of bleeding, pharyngeal pain, eating obstruction, and dyspnea.¹ Nevertheless, another study reported the patient complained of having progressive foreign-body sensation in the throat and intermittent inspiratory stridor.⁴ Summarizing from several studies, most angio-fibromas present as an asymptomatic mass, except for nasopharyngeal and retroperitoneal tumors.¹⁸ Tumor located in the nasopharynx frequently presents with epistaxis and persistent nasal obstruction.^{12,18}

The management of angio-fibromas, in general, is surgery or excision of the mass.^{19,20} One study removed the mass in the hypopharynx completely by coblation, while the other was removed by trans-endoscopic approach. It was found that the patient was asymptomatic at 3 months follow-up and no recurrence 6 months after excision, whereas there was no abnormality found on the other patient after 3 years of follow-up.^{1,4}

In this report, preoperative tracheostomy and mass biopsy by micro-laryngoscope approach were done. The mass was successfully removed surgically approach transcervical

Case Report

incision and thus far no recurrence or post-surgical complications were found one year after excision. Further, follow-up is needed to evaluate the recurrence of tumors in prolonged period.

Conclusion

Angiofibroma is a benign and slow-growing mass. The patient reported in this report showed no significant complaints which could disturb the airway or eating passage. Management of this case is the same as angiofibroma in general, by surgery approach transcervical incision. The post-operative condition of the patient was also within the normal limit. Limited reports due to the extremely rare incidence of this case are not sufficiently representative and more reports are needed to describe further characteristics and prognosis of this disease.

References

1. Liu Y, Xu Y, Wang Q, Chen Q. Cellular angiofibroma in the hypopharynx: A case report. *Medicine (Baltimore)*. 2019; 98(50):e18385.
2. Dubey SP, Schick B. *Juvenile Angiofibroma*. 1st Edition. Switzerland:Springer; 2017; 265-70.
3. Lee BH. Parapharyngeal angiofibroma: A case report. *Iran J Radiol*. 2015; 12(3):1-3.
4. Hsieh ST, Guo YC, Tsai TL, Chen WYK, Huang JL. Angiofibroma of the hypopharynx. *J Chinese Med Assoc*. 2004; 67(7):373-5.
5. Nandhini J, Ramasamy R, Kaul RN, Austin RD. Juvenile primary extranasopharyngeal angiofibroma, presenting as cheek swelling. *J Oral Maxillofac Surg Med Pathol*. 2018; 22(1):S73-6.
6. Singh GB, Shukla S, Kumari P, Shukla I. A rare case of extra-nasopharyngeal angiofibroma of the septum in a female child. *J Laryngol Otol*. 2017; 2(1):1-4.
7. Flucke U, Krieken JHJM Van, Mentzel T. Cellular angiofibroma : analysis of 25 cases emphasizing its relationship to spindle cell lipoma and mammary-type myofibroblastoma. *Mod Pathol*. 2011; 24(1):82-9.
8. Windfuhr J, Vent J. Extranasopharyngeal angiofibroma revisited. *Clin Otolaryngol*. 2018; 43(1):p199-222
9. Lerner C, Wemmert S, Schick B. Preliminary analysis of different microRNA expression levels in juvenile angiofibromas. *Biomed Rep*. 2014; 2(6):835-8.
10. Li W, Ni Y, Lu H, Hu L, Wang D. Current Perspectives on the origin theory of juvenile nasopharyngeal angiofibroma. *Discov Med*. 2019; 27(150):245-54.
11. Doddy J, Adil EA, Trenor CC, Cunningham MJ. The genetic and molecular determinants of juvenile nasopharyngeal angiofibroma: a systematic review. *Ann Otol Rhinol Laryngol*. 2019; 128(11):1061-72
12. Schick B. Juvenile nasopharyngeal angiofibroma. *J Oral Maxillofacial Pathol*. 2016; 20(2):3030.
13. Lerra S, Nazir T, Khan N, Qadri MS, Dar NH. A case of extranasopharyngeal angiofibroma of the ethmoid sinus : A distinct clinical entity at an unusual site. *Sage Journals*. 2012; 91(2):E15-7.
14. David MJC, Trinidad CAJ, Chua AH. Extranasopharyngeal Angiofibroma of the Larynx. *PJOHNS*. 2010; 25(1):23-5.
15. Arulappan LAS. Extranasopharyngeal angiofibroma in an adolescent male: a case report. *Int J Otorhinolaryngol Head Neck Surg*. 2019;5(5):1416.
16. Ma HJ, Huang HN, Li L, Chen S, Zhang RY. Clinicopathological characteristic of angiofibroma of soft tissue: report of three cases. *Int J Clin Exp Pathol*. 2018; 11(7):3777-84.
17. Mishra A, Jaiswal R, Amita P, Mishra SC. Molecular interactions in juvenile nasopharyngeal angiofibroma: preliminary signature and relevant review. *Eur Arch Oto-Rhino-L*. 2019; 276(3):93-100.
18. Erdur ZB, Yener HM, Yilmaz M, Karaaltin AB, Inan HC, Alaskarov E, et al. Cellular Angiofibroma of the Nasopharynx. *J Craniofac Surg*. 2017 Nov; 28(8):e720-2.
19. Nicolai P, Schreiber A, Bolzoni Villaret A. Juvenile Angiofibroma: Evolution of Management. *Int J Pediatr*. 2012; 1(2):1-11.
20. Dewi YA, Nazar IB. Management of Juvenile Nasopharyngeal Angiofibroma in a Referral Hospital in West Java, Indonesia. *Althea Med J*. 2020; 7(1):45-50.